LE FRATTURE DI FEMORE DISTALE IN ETÀ PEDIATRICA

CLINICA **O**RTOPEDICA e **T**RAUMATOLOGICA
UNIVERSITA' SAPIENZA di **R**OMA

Injury

Volume 38 Issue 8, August 2007 Pages 913–922

The epidemiology of fractures in children

Louise Rennie et al.

Table 1.

The basic epidemiology of paediatric fractures in Edinburgh in 2000

Fracture	%	Age (year)	Male:female (%)
Distal radius/ulna	32.9	9.9	55:45
Finger phalanges	19.5	10.6	66:34
Metacarpus	7.6	12.8	85:15
Distal humerus	7.4	6.8	56:44
Clavicle	7.3	8.3	71:29
Radius/ulna diaphysis	5.4	7.8	64:36
Metatarsus	4.8	10.0	56:44
Ankle	3.9	10.9	58:42
Toe phalanges	3.0	10.9	51:49
Proximal radius/ulna	2.8	8.5	42:58
Tibia and fibula diaphysis	2.5	8.9	67:33
Proximal humerus	1.8	9.5	36:64
Distal tibia	1.7	10.0	66:34
Scaphoid	1.3	12.7	79:21
Femoral diaphysis	0.7	6.3	69:31
Humeral diaphysis	0.4	10.7	75:25
Distal femur	0.3	6.6	83:17
Proximal tibia	0.2	11.2	100:0
Patella	0.2	9.8	75:25
Pelvis	0.2	8.8	75:25
Talus	0.1	10.9	67:33
Calcaneus	0.1	11.2	100:0
Midfoot	0.1	9.3	67:33
Thoracic spine	0.1	8.0	67:33
Cervical spine	0.1	13.4	100:0
Proximal femur	0.1	10.5	100:0
Lumbar spine	0.05	9.2	0:100

The prevalence of different fractures together with the average age and gender ratio of the patients is shown.

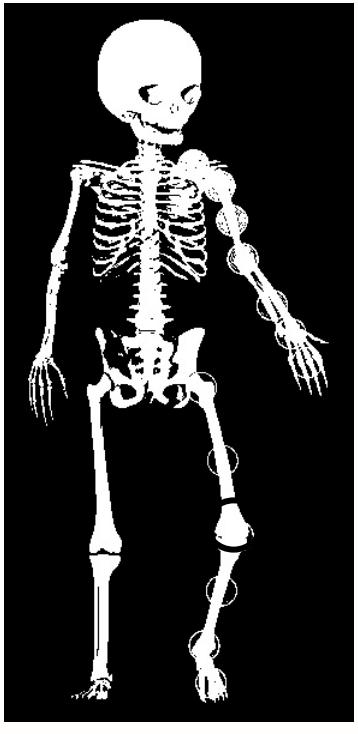

Table 4

The basic epidemiology for each type of blunt trauma, with the five commonest fractures for each mechanism

Type of blunt trauma	Prevalence (%)	Mean age (year)	Male:female (%)	Upper:lower limb (%)	Five commonest fractures
Crush	20.3	7.9	59:41	84:16	Finger phalanges (75.9%)
					Toe phalanges (9.6%)
					Metacarpus (6.0%)
					Metatarsus (3.6%)
					Distal radius (2.4%)
Flexion/extension	16.4	11.3	69:31	93:7	Finger phalanges (70.1%)
					Distal radius (11.9%)
					Metacarpus (9.0%)
					Toe phalanges (4.5%)
					Metatarsus (3.0%)
Direct blow	11.3	10.5	76:24	78:22	Metacarpus (23.9%)
					Finger phalanges (21.7%)
					Distal radius (13.0%)
					Radius/ulna diaphysis (10.9%)
					Toe phalanges (6.7%)
Assault	0.5	7.3	75:25	50:50	Distal femur (25.0%)
					Proximal humerus (25.0%)
					Clavicle (25.0%)
					Metatarsus (25.0%)

- **FRATTURE DELLA METAFISI DISTALE**

- **FRATTURE DELLA CARTILAGINE DI ACCRESCIMENTO DISTALE**
  (+ frequenti)

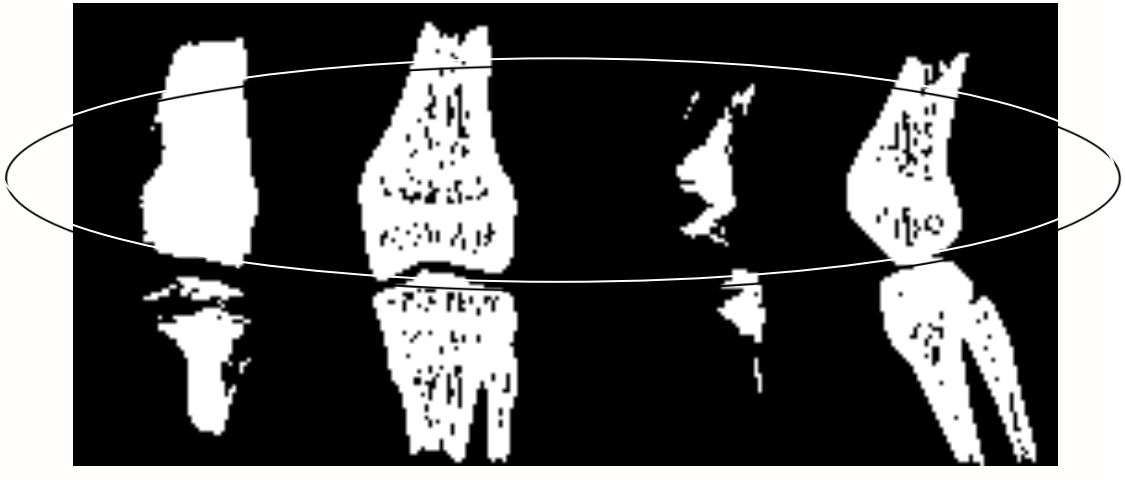

➢FRATTURE DELLA METAFISI DISTALE (raramente senza distacco epifisario)

Molto meno frequenti delle fratture diafisarie
Traumi ad alta energia

Fratture più frequenti in caso di abuso

CLASSIFICAZIONE AO

33-M Distal metaphyseal fractures

Simple | Multifragmentary | Simple | Multifragmentary

33-M/2.1

Torus/buckle

33-M/3.1

Complete

33-M/3.2

33-M/7

Bilateral avulsion

33-M/7

Medial avulsion

33-M/7

Lateral avulsion

33-M Distal metaphyseal fractures

Simple Multifragmentary

33-M/2.1

Torus/buckle

Immobilizzazione in app gessato
per 3-4 settimane

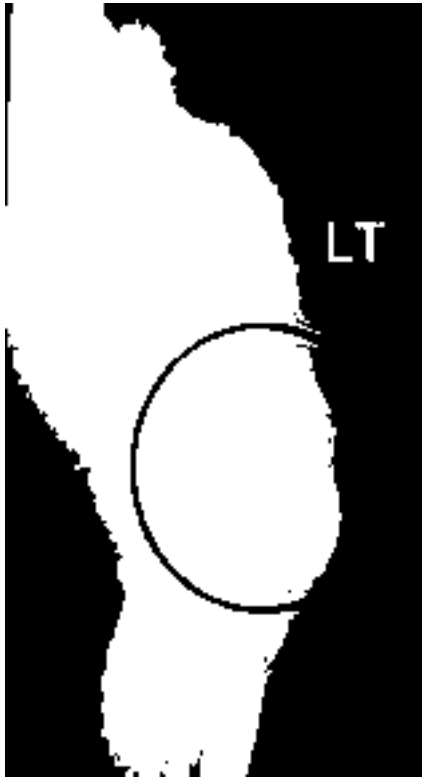

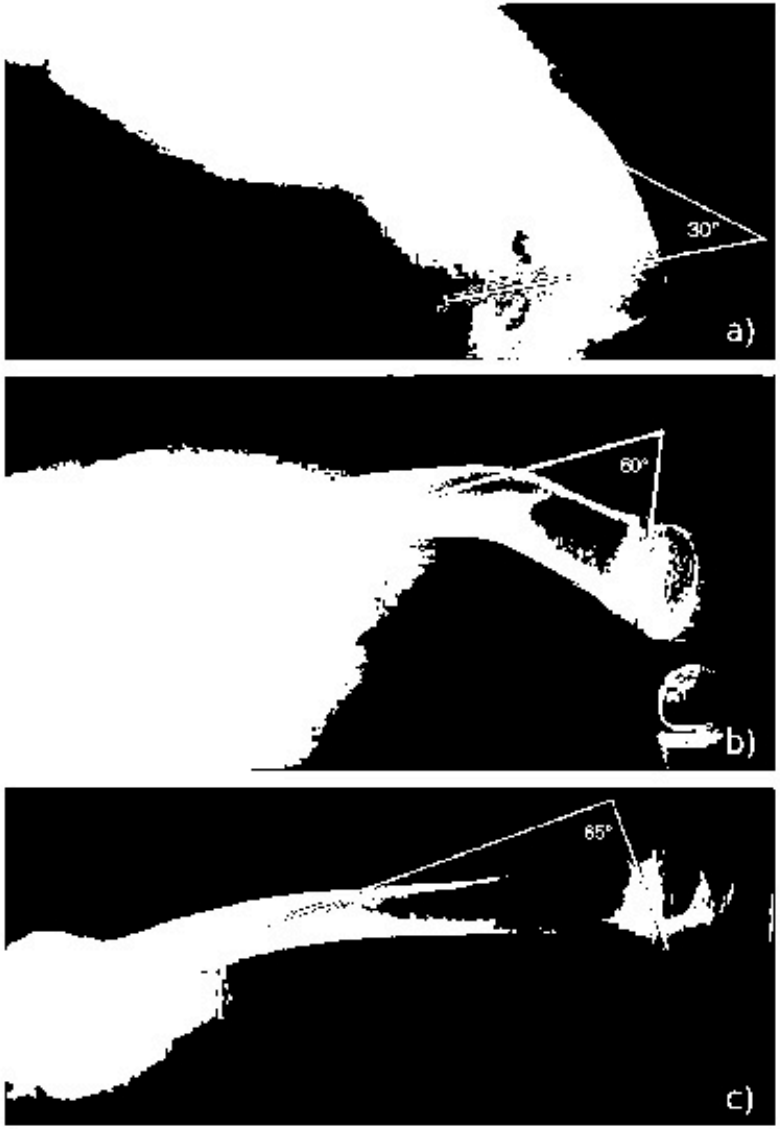

La cartilagine d'accrescimento femorale distale contribuisce al 70% della crescita in lunghezza del femore

Alto potere di rimodellamento femore distale

Tollerabilità di scomposizione: 35°



33-M Distal metaphyseal fractures

Simple | Multifragmentary

33-M/3.1 | 33-M/3.2

Complete

Alto rischio vascolare
S. compartimentale

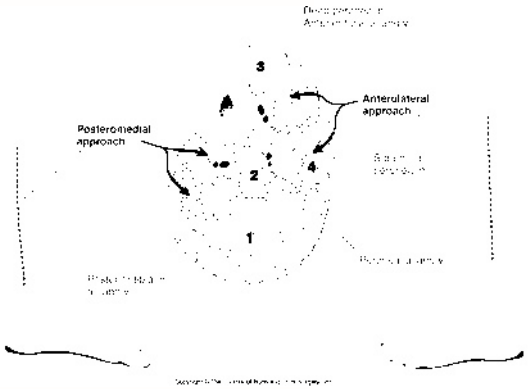

Nostra scuola:
URGENZA

SAOTS
South African Orthopaedic Trauma Society

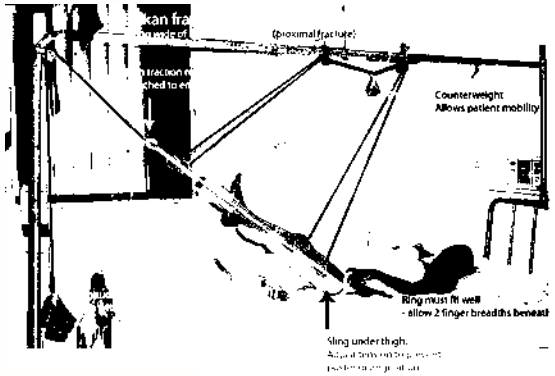

Skin traction e
successiva immobilizzazione in gesso

INDICAZIONI:
- Peso <12 kg
- Cute intatta

JBJS The Journal of Bone & Joint Surgery

Comparison of Titanium Elastic Nails with Traction and a Spica Cast to Treat Femoral Fractures in Children

John M. Flynn et al

J Bone Joint Surg Am, 2004 Apr; 86 (4): 770 -777

83 paz
6-16 anni
Frattura III medio e distale di femore

35 paz
Trazione e apparecchio gessato

48 paz
Sintesi percutanea con TEN

COMPLICANZE

34%

21%

Più breve ospedalizzazione
Deambulazione autonoma più precoce
Rientro a scuola più breve

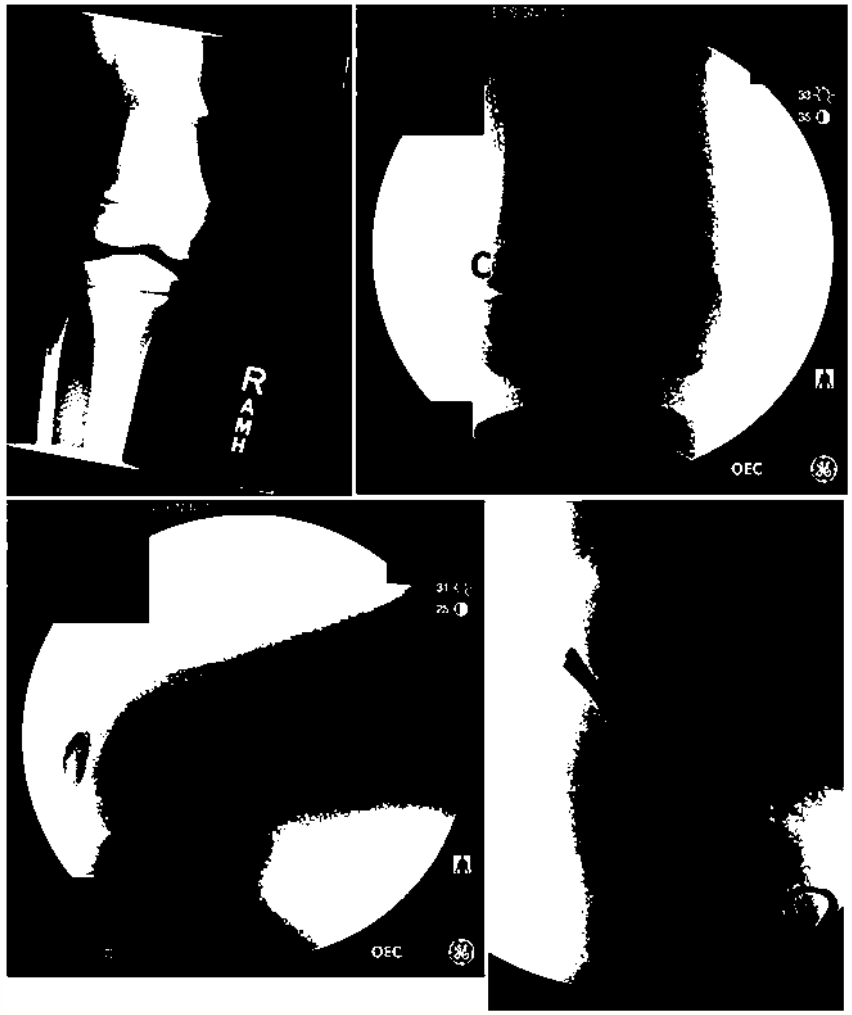



Complications of Elastic Stable Intramedullary Nailing in Pediatric Fracture Management
Shital N. Parikh et al. *J Bone Joint Surg Am*, 2012 Dec 19; 94 (24): e184 .

JBJS The Journal of Bone & Joint Surgery

WWW.PIETROPERSIANI

Riduzione incruenta e Sintesi percutanea con fili di K
Immobilizzazione in gesso femoro podalico per 5 settimane
Rimozione fili di K dopo 4 settimane

Fratture spiroidi o non trasverse

Viti cannulate posizionate parallelamente alla fisi



Frattura metafisaria
distante almeno 7 cm dalla superficie condilare

Chiodi elastici per via retrograda
Incrociati nel punto più stretto del canale midollare

2 chiodi di stesso diametro
30-40% del diametro midollare nel punto più stretto

➢FRATTURE DELLA CARTILAGINE DI ACCRESCIMENTO DISTALE

1 – 6 % di tutti i distacchi epifisari
3% di tutte le fratture epifisarie

PIÙ FREQUENTI: SH I e II

Traumi ad alta energia (< 11 aa)

Infortuni sportivi in età adplescenziale

(2/3 delle fratture di femore distale)

Meccanismo varo/valgo

Iperestensione del ginocchio

Il piatto d'accrescimento femorale distale contribuisce al
70% crescita in lunghezza del femore
40% crescita complessiva dell'arto inferiore

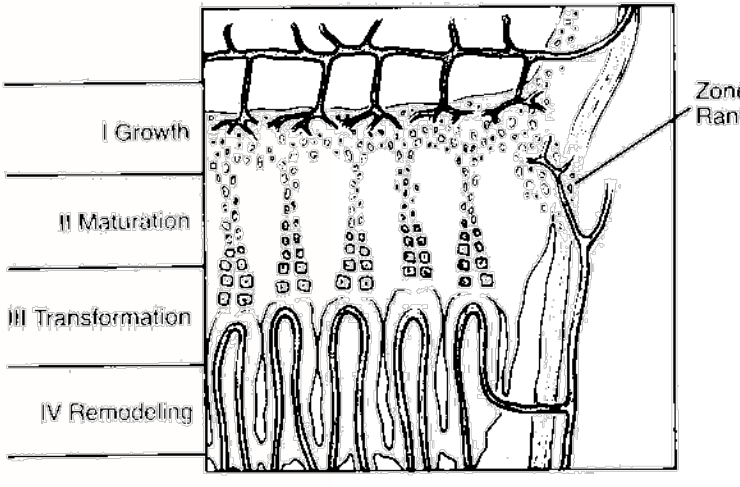

Riseborough EJ, et al. JBJS(A) 1983;65:885.

40% arresto di crescita

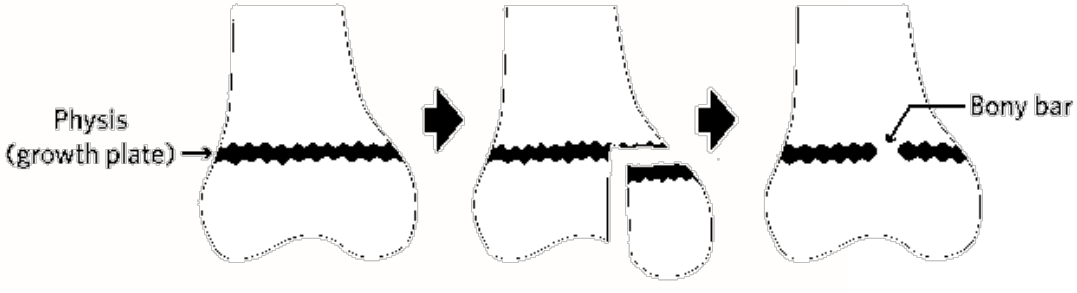

Growth Plate Fractures of the Distal Femur. *Wall, Eric J. Et al*.
Journal of Pediatric Orthopaedics. Volume 32, June 2012, p S40–S46

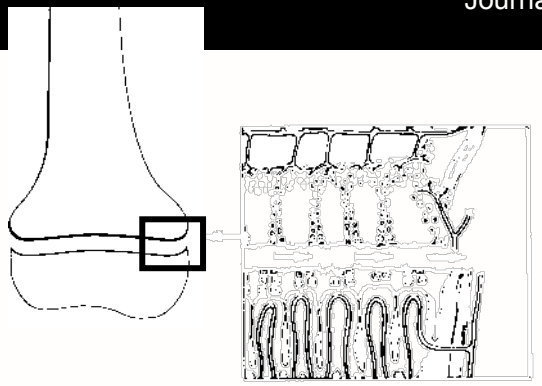

DISTACCO SH 1

Dolore circonferenziale intorno alla cartilagine di accrescimento

Ginocchio esteso, linea equatoriale della rotula corrisponde alla fisi

Stress in varo valgo provoca dolore acuto

SH I COMPOSTA
Gesso femoro-podalico per 4 settimane

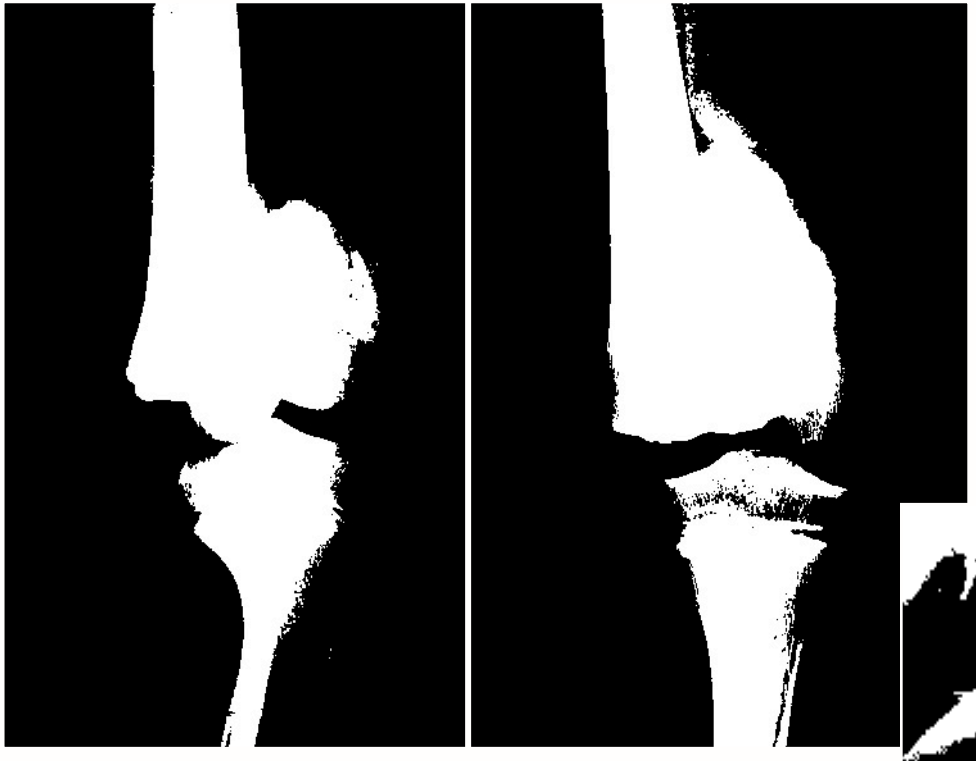

RIDUZIONE INCRUENTA

75% TRAZIONE 25% MANIPOLAZIONE

SH I SCOMPOSTA
Riduzione chiusa + sintesi percutanea con fili di K

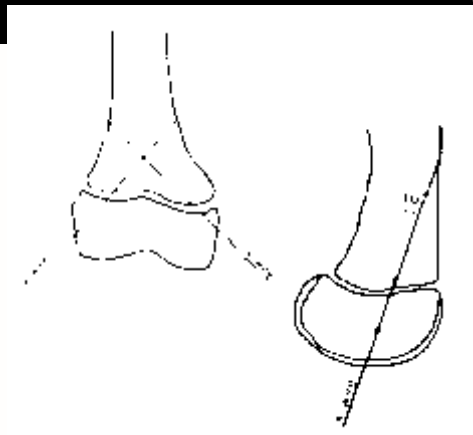

RIMOZIONE DEI FILI: dopo 4 settimane

Distal Femoral Physeal Fixation: Are Smooth Pins Really Safe?
Dahl, William J. Et al.
Journal of Pediatric Orthopaedics Volume 34(2), March 2014, p 134–138


Figure 1


Figure 2


Figure 3


Figure 4

30 conigli
1° pin: Porz centrale della metà laterale della fisi
2° pin: in una delle 2 aree evidenziate in fig 1
15 conigli pin in zona PERIFERICA
15 conigli in zona CENTRALE

Dopo 4 sett: Rimozione pin

Dopo 8 sett:
- Controllo tc faxitron
- Esame istologico della fisi


Figure 5 Figure 6

3 conigli (1 nel 1° gruppo e 2 nel 2° gruppo)
Presentavano lesione della cartilagine
Nessuno evidenziava presenza di ponti ossei

Growth Plate Fractures of the Distal Femur. Wall, Eric J. Et al.
Journal of Pediatric Orthopaedics. Volume 32, June 2012, p S40–S46

DISTACCO SH 2

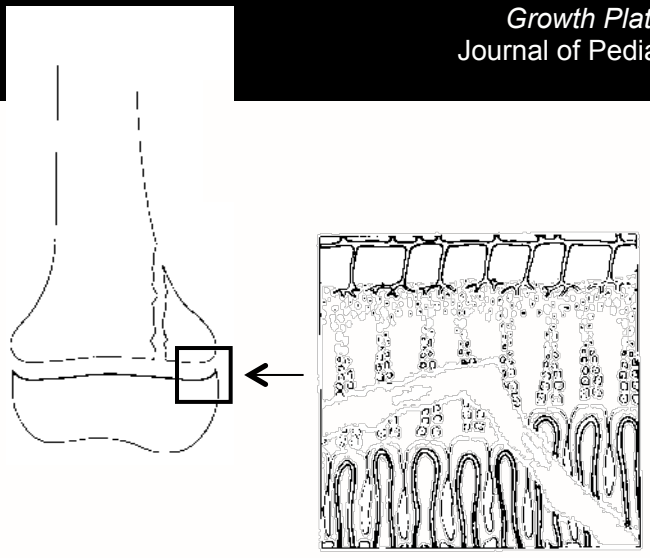

Dolore moderato
Emartro

SH II COMPOSTA
Rara

Gesso femoro-podalico per 4 settimane

RX dopo 1 settimana per verificare se presenti scomposizioni secondarie in gesso

SH II SCOMPOSTA

Se frammento >2,5 cm

ORIF/sintesi con vite parallela a fisi

1 o 2 Viti cannulate da 4,5-7,3mm

+ femoro podalico per 3 settimane

Assicurarsi che le viti fissino la frattura

Frammento metafisario anteriore o posteriore

se piccolo frammento
< 2,5 cm

Orif con fili di k percutanei



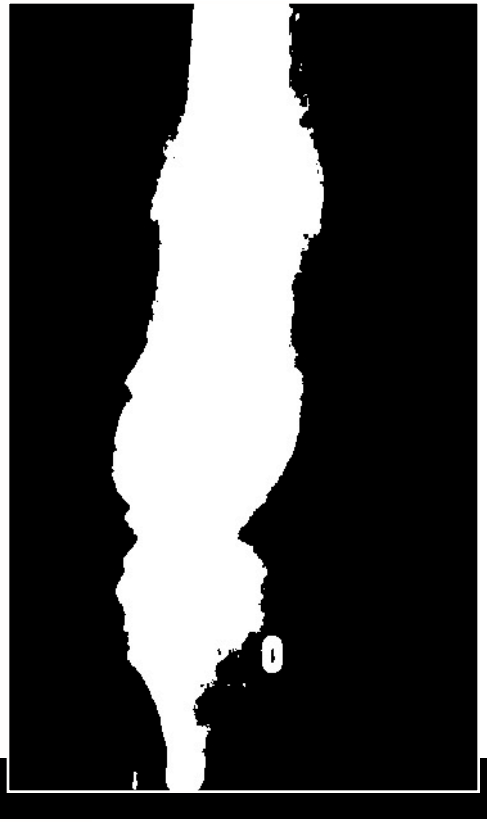

Growth Plate Fractures of the Distal Femur. Wall, Eric J. Et al.
Journal of Pediatric Orthopaedics. Volume 32, June 2012, p S40–S46

DISTACCO SH 3

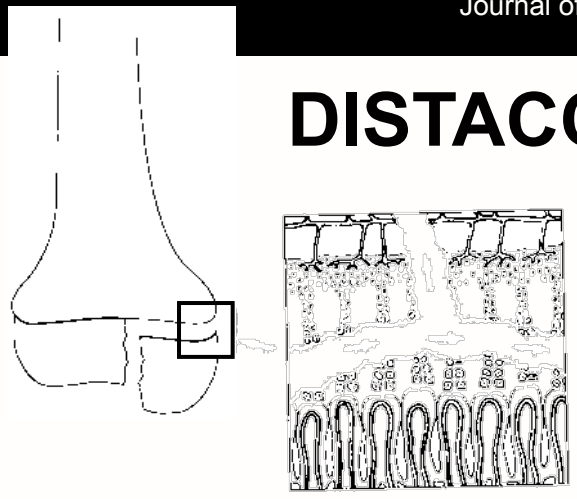

SH III e IV COMPOSTE e SCOMPOSTE
Indicazione chirurgica
ORIF con vite cannulata 4.5-7.5 mm

Incisione pararotulea di circa 3 cm
Palpazione diretta della superficie articolare
Perfetta riduzione e fissazione

DISTACCO SH 4

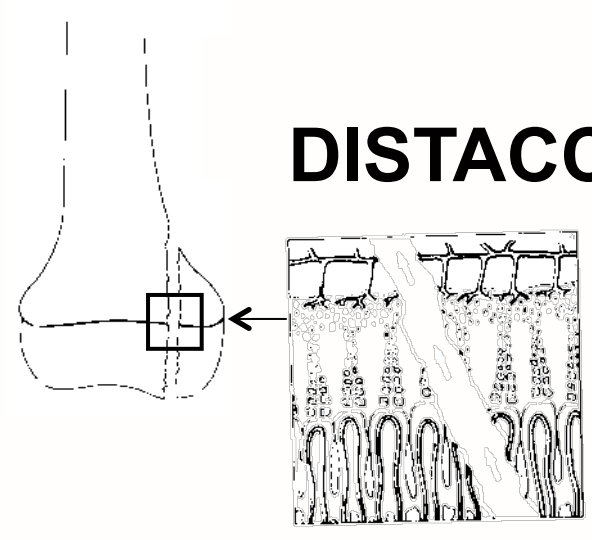

Immagine amplioscopica
sottotima il gap e lo step-off del sito di frattura

SH III

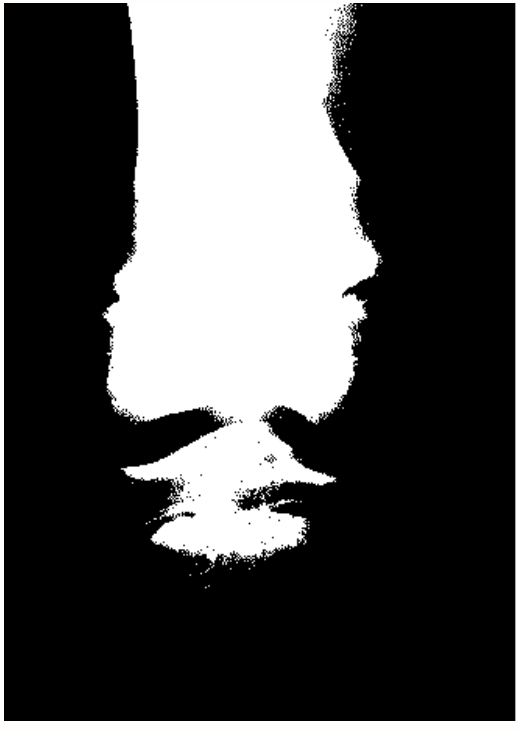

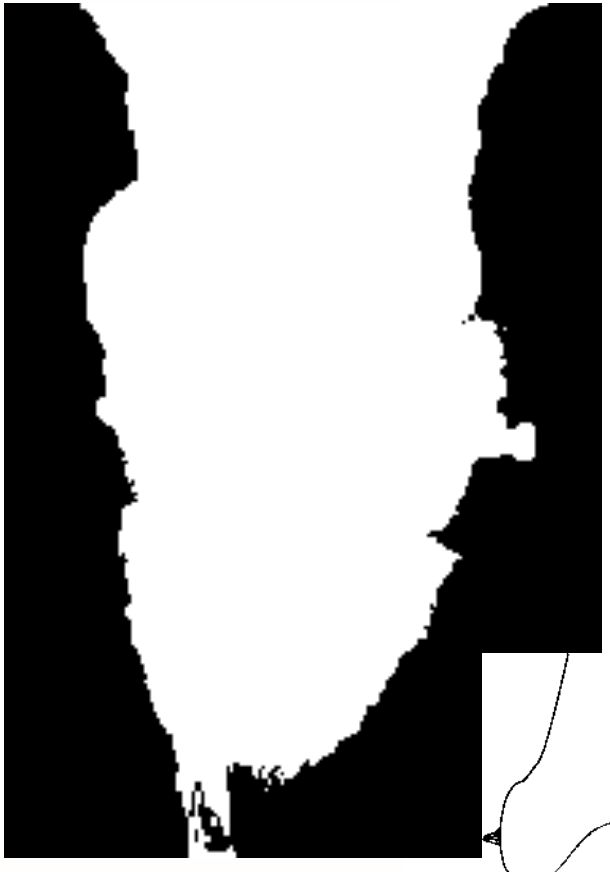

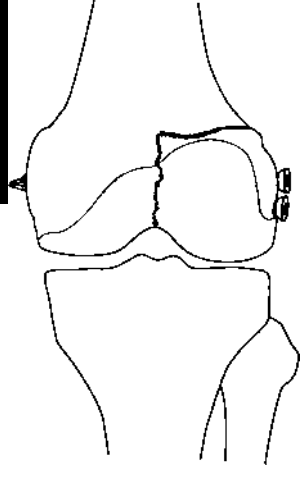

SH IV



L 78
able

L 78
SERIES: #1

JOHNS HOPKINS HO
SERIES: #1
OEC

JOHNS HO
OE

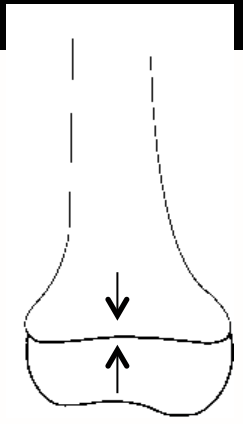

DISTACCO SH 5



DISTACCO SH 6

Avulsione della zona periferica della fisi

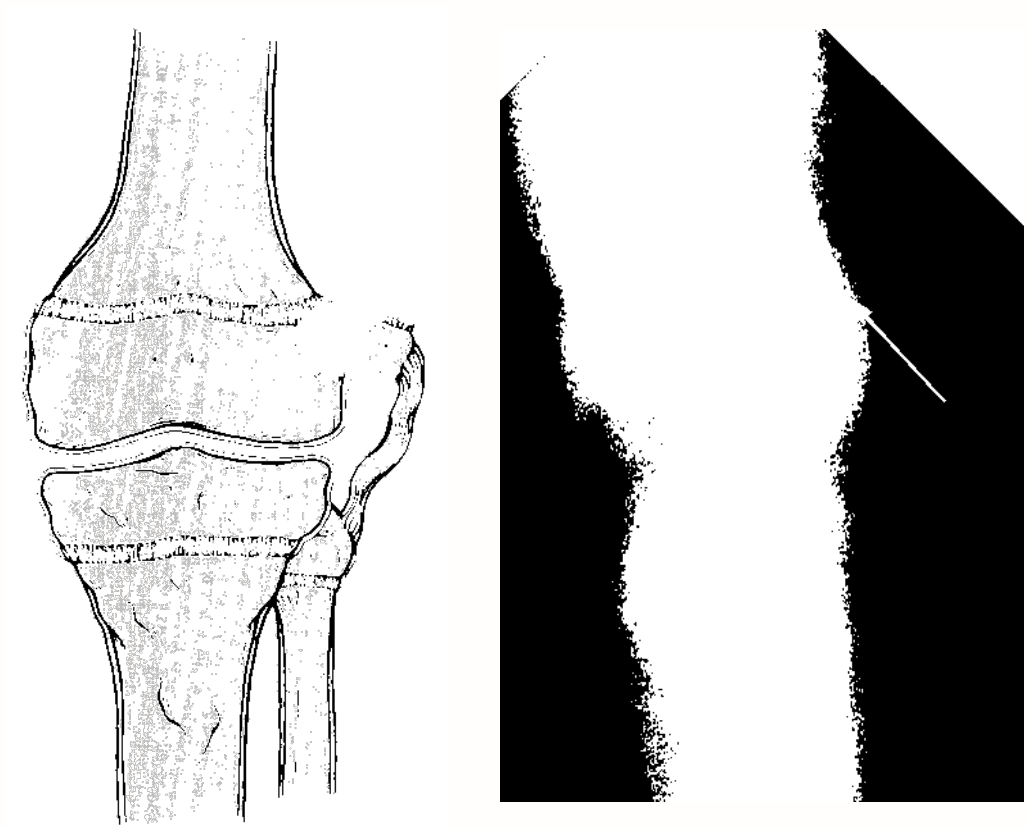

Il trattamento mira a

MINIMIZZARE ULTERIORI DANNI ALLA CARTILAGINE D'ACCRESCIMENTO

COMPLICANZE

- **Precoci**
  - Sindromi compartimentali
  - Complicazioni vascolari (10%)
  - Complicazioni nervose (3%)

- **Tardive**
  - Instabilità e lesioni degenerative (20%)
  - Ritardi della crescita (10%)

FATTORI FAVORENTI	Trauma violento Apertura del focolaio di frattura Infezione Errori di trattamento (riduzione forzata, osteosintesi inappropriata)

Controlli clinici ed rx fino a 24 mesi post trattamento

CLASSIFICAZIONE DEGLI ARRESTI PARZIALI DI CRESCITA SEC. BRIGHT

TIPO I PERIFERICO

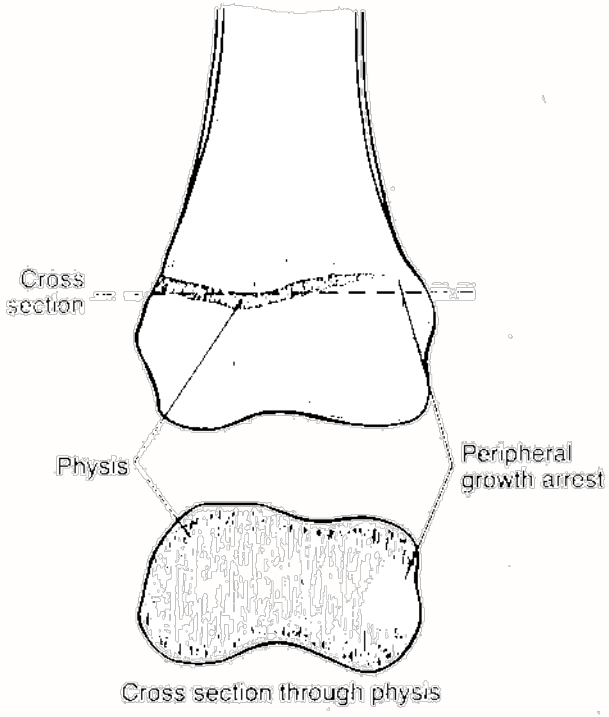

TIPO II CENTRALE

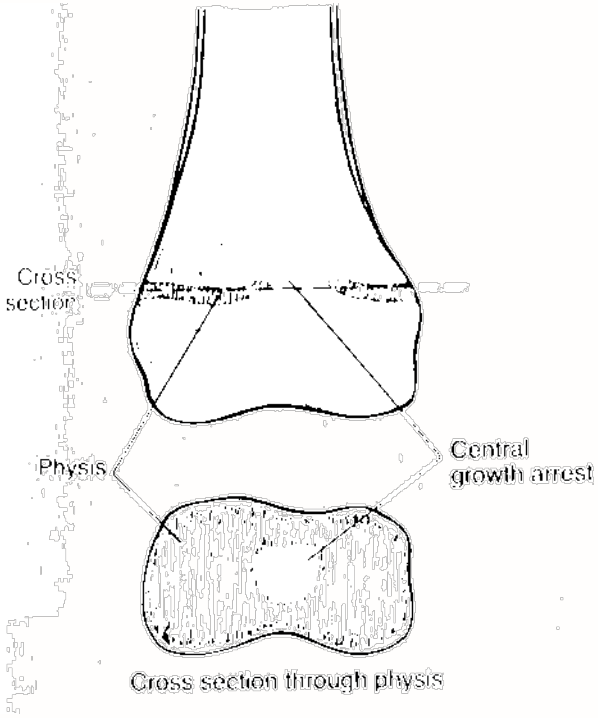

TIPO III COMBINATO

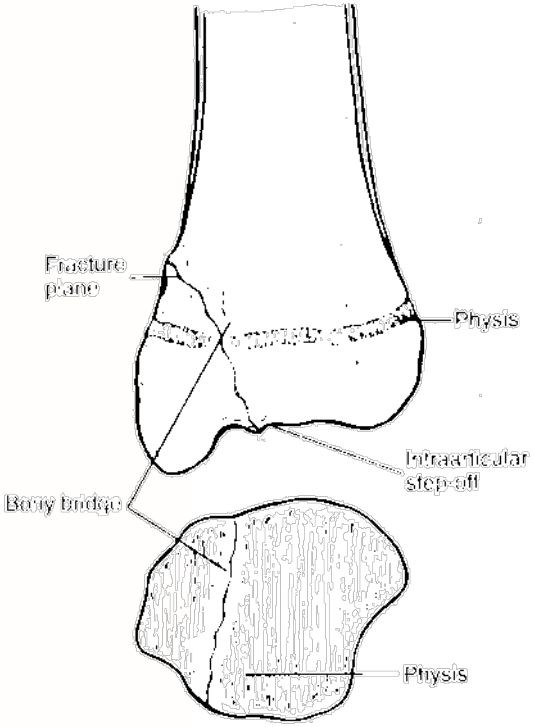

DEVIAZIONI ASSIALI

ETEROMETRIE

Rmn 1 anno post trattamento per SH 1

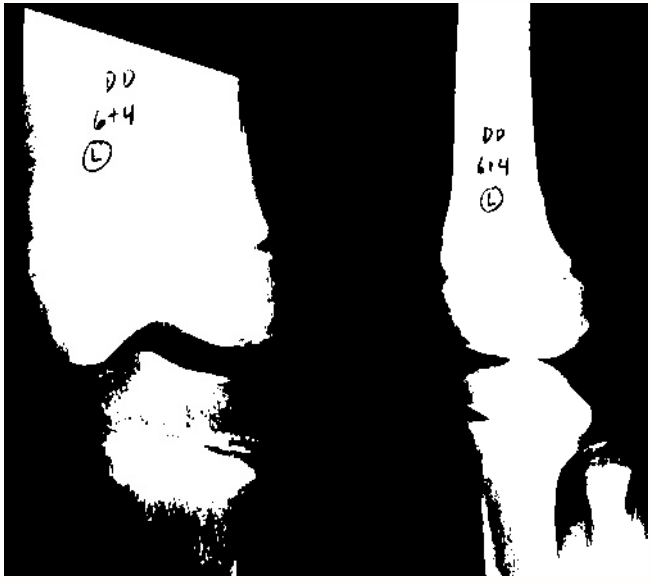



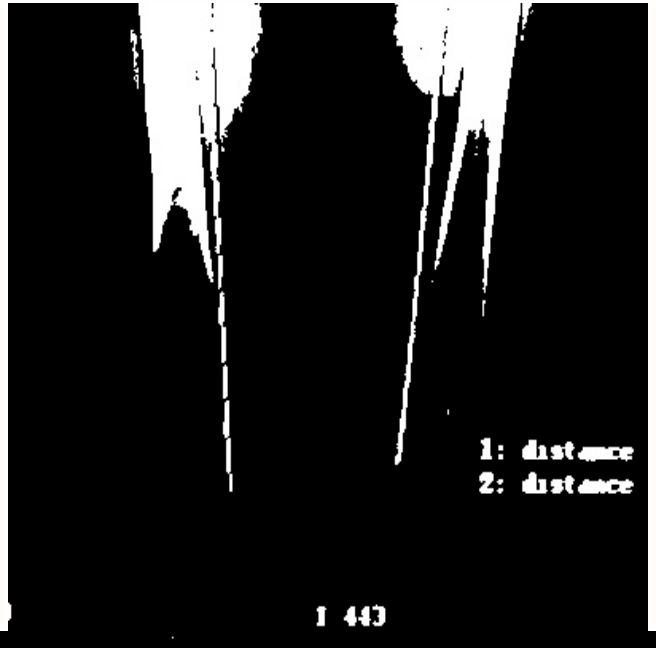

INTRAPPOLAMENTO PERIOSTALE

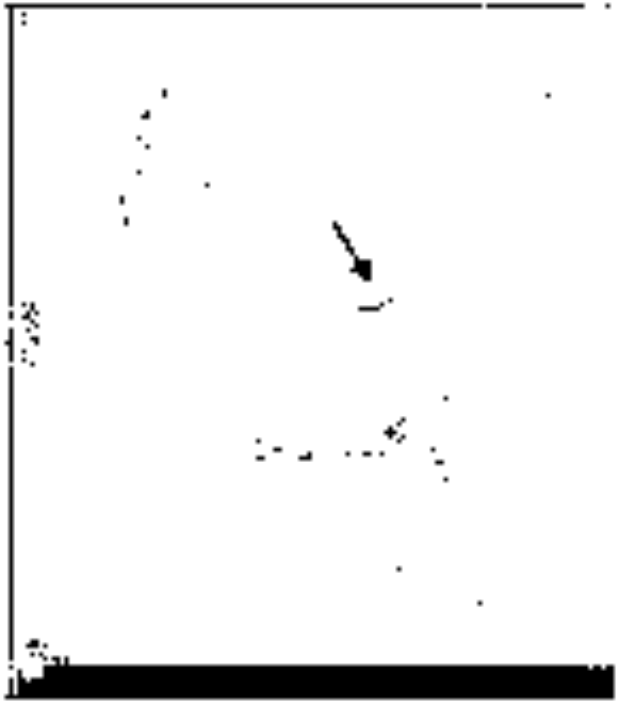

CAUSA PIÙ FREQUENTE ARRESTI DI CRESCITA
NEI DISTACCHI DI TIPO SH I-II

Acta Orthop Belg. 2011 Oct. Periosteal entrapment in distal femoral physeal fractures: harbinger for premature physeal arrest? Segal LS, Shrader MW.

Pediatr Radiol. 2011 Dec. MRI diagnosis of trapped periosteum following incomplete closed reduction of distal tibial Salter-Harris II fracture. Raman S, Wallace EC.

TAKE HOME MESSAGE

DIAGNOSI E TRATTAMENTO PRECOCE

RIDUZIONE CHIUSA NON VIOLENTA - EVITARE MANIPOLAZIONI RIPETUTE

RUOLO DELLA RMN
indagare con rmn riduzioni non soddisfacenti o difficoltose
(possibile interposizione periostale)

EVITARE ATTRAVERSARE CARTILAGINE DI ACCRESCIMENTO CON MDS

INFORMARE I GENITORI DI POSSIBILI ESITI
(che possono presentarsi anche a distanza di anni dal trauma)