SAPIENZA
UNIVERSITÀ DI ROMA

FRATTURE DI POLSO IN ETA' PEDIATRICA

Pietro Persiani



Fratture di polso in età pediatrica

20-35% di tutte le fratture nei bambini

75% delle fratture di avambraccio

10-14 anni

Table 4. Distribution of injury mechanisms

Injury mechanism	Events	Proportion (%)
Fall on the same plane	2,489	24
Collision with/struck by physical object, another person, or animal	2,407	24
Fall between planes	2,319	23
Traffic	1,227	12
Downhill fall	1,099	11
Crushed, cut or stuck	334	3
Other	328	3
Total	10,203	100

Figure 2. Sex-specific fracture incidence and incidence r
year of age.

Epidemiology of fractures in children and adolescents

Increased incidence over the past decade: a population-based study from northern Sweden

Erik M Hedstrain, Ola Svensson, Ulrica Bergstrom, and Piotr Michno

Landin LA: Fracture patterns in children: analysis of 8682 fractures with special reference to incidence, etiology and secular changes in a Swedish urban population 1950-1979, *Acta Orthop Scand Suppl* 202:1-109, 1983.

Landin LA: Epidemiology of children's fractures, *J Pediatr Orthop* 6:79- 83, 1997.

METAFISARIE

EPIFISARIE

Epifisarie

20% di tutti i distacchi epifisari nei bambini
In ordine di frequenza secondi solo a quelli delle falangi

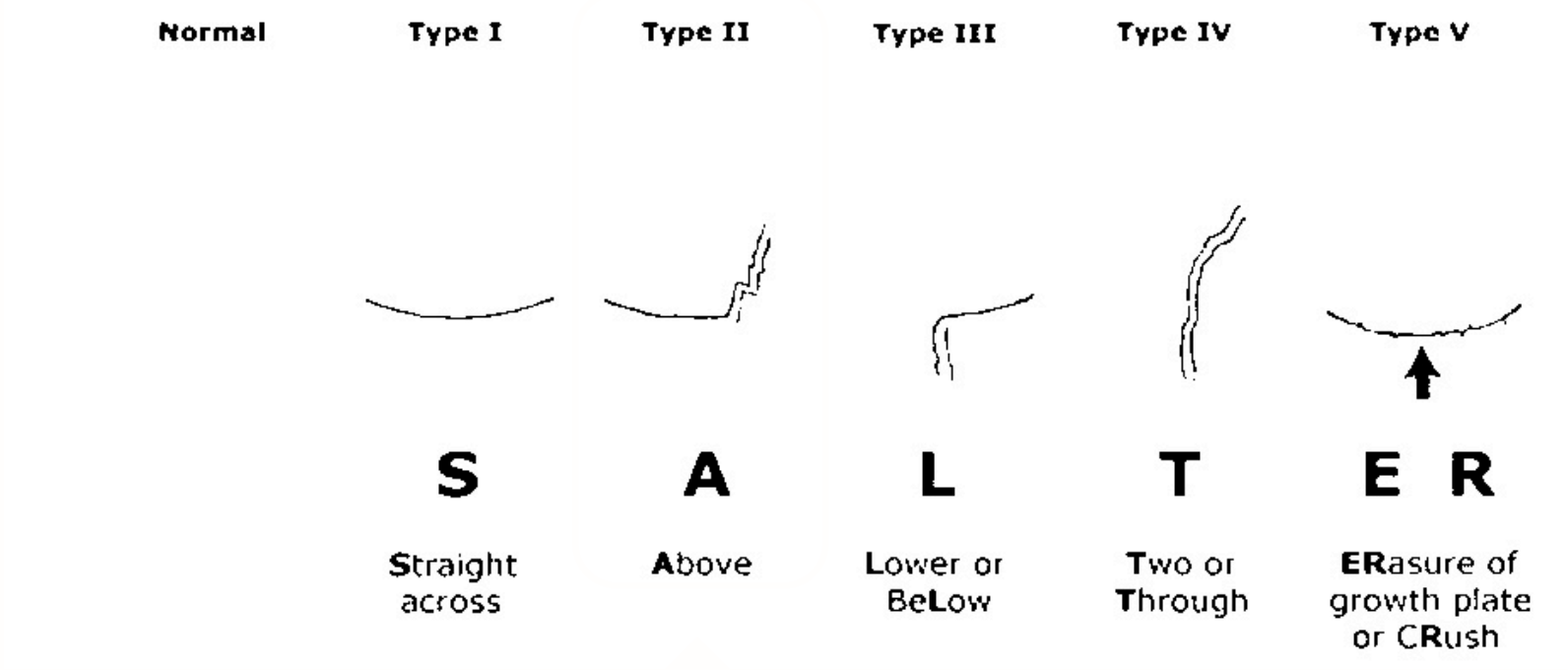

Metafisarie

- Torus (Buckle fracture)
- Greenstick
- Completa

Torus

- Più frequente tra le fratture di radio nel bambino
- Rottura di una sola corticale
- Trattamento con splint per 3 settimane

THE JOURNAL OF BONE & JOINT SURGERY (BR)

Simple treatment for torus fractures of the distal radius

J. S. Davidson, D. J. Brown, S. N. Barnes, C. E. Bruce
Alder Hey Children's Hospital, Liverpool, England

Greenstick

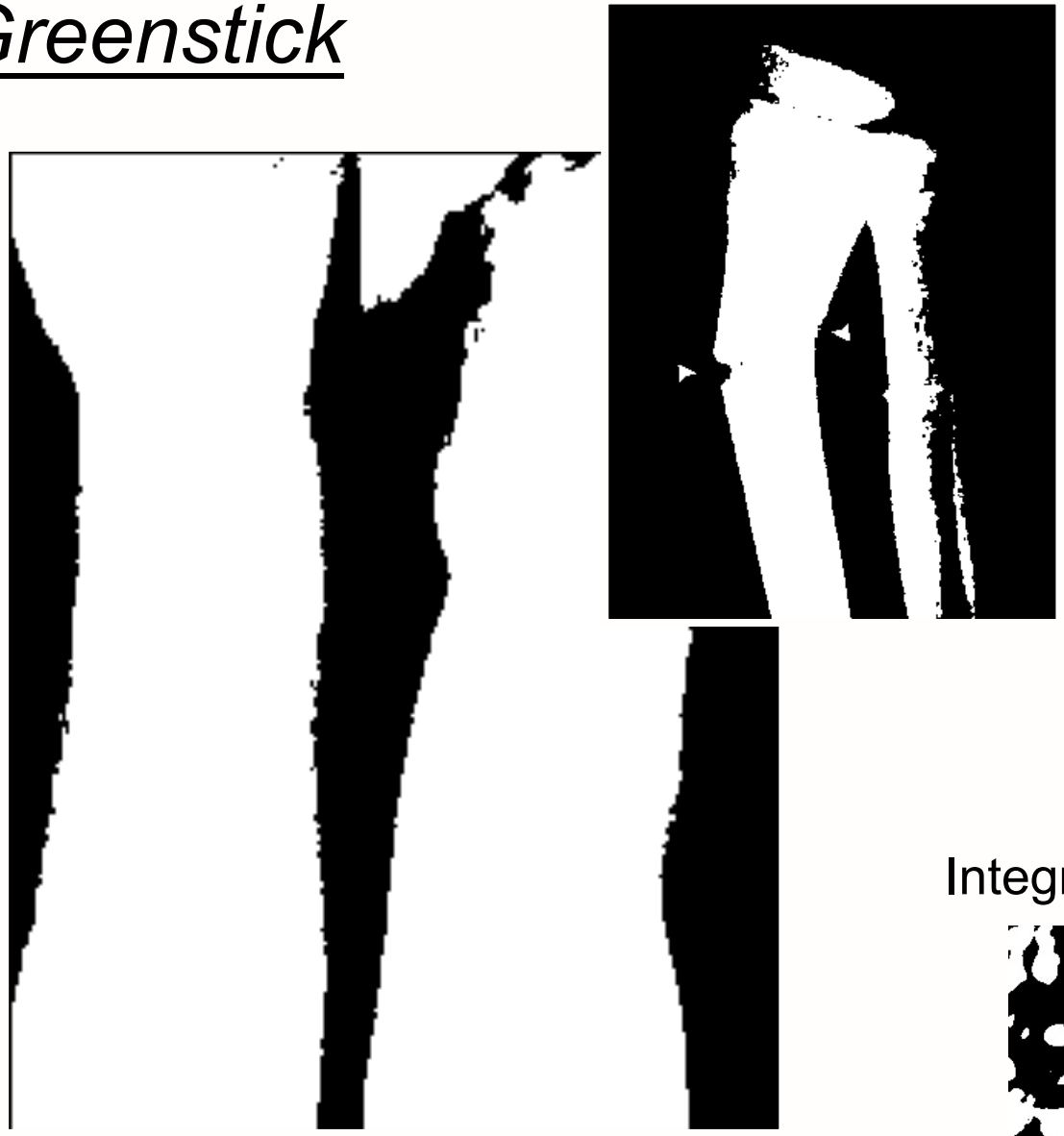

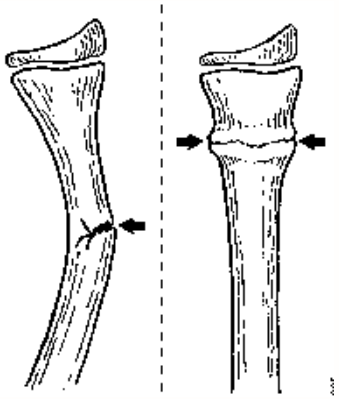

Integrità di una sola corticale

Completa metafisaria

La linea di frattura attraversa completamente la metafisi del radio distale
Composta o scomposta
Associata o meno a frattura dell’ulna

Frattura lussazione del Galeazzi

Frattura di radio distale associate a distruzione del ARUD



- “Galeazzi-simili” sono considerate le fratture di radio distali associate a distacco epifisario ulna distale o avulsione dello stiloide ulnare

AUTHORS' CONCLUSIONS

Implications for practice

The limited evidence available from randomised controlled trials supports the use of removable splintage or supports for buckle fractures with the option of clinical review rather than plaster cast for three weeks requiring a return for removal and assessment. However, the best type of splintage is not established.

For children whose displaced fractures have been reduced, there is some preliminary evidence suggesting that below-elbow casts do not increase, and may in fact reduce, the risk of redisplacement compared with above-elbow casts. Furthermore, below-elbow casts allow earlier return to activities, avoid elbow stiffness and are more comfortable. If shorter casts are better then the need to consider supinated, neutral or pronated positions of the forearm in above-elbow immobilisation is redundant. Surgical fixation of reduced fractures using percutaneous wiring maintains the reduction more effectively than above-elbow casts. The limited data available indicated no advantage in function at three months. There was insufficient evidence to determine the best treatment for the different types of displaced fracture, including radial fractures where the ulna is intact.

Trattamento incruento

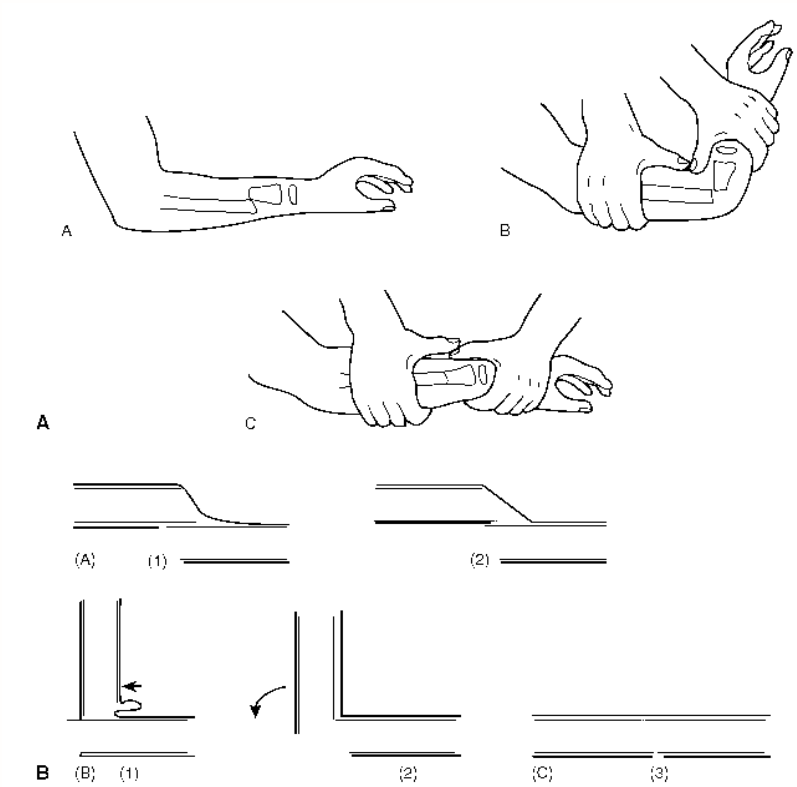

A causa dello **spesso periostio** del bambino la manovra di riduzione può non essere così semplice

- E' necessario inizialmente iperflettere nel senso della deformità
- Trazionare longitudinalmente
- E solo alla fine correggere la deformità

Apparecchio gessato brachio-metacarpale poi
Antibrachio-metacarpale per altre
(a seconda della frattura)

“Repeated efforts at reduction do nothing more than grate the plate away.”

“These injuries unite quickly, so that attempts to correct malposition after a week are liable to do more damage to the plate than good.”

Rang, 2005



Quando operare?

- Fratture instabili
- Fratture irriducibili (interposizione tessuti molli, spira ossea)
- Lesioni neurovascolari
- Fratture esposte (indicato il fissatore esterno)
- Presenza di fratture omerali (floating elbow)

- Distacchi Epifisari SCOMPOSTI



Trattamento cruento

Riduzione e osteosintesi con fili di Kirschner





«Tecnica joystick»

- Cercare sempre di evitare la fisi
- Quando non è possibile.. (distacchi epifisari) attraversarla in maniera perpendicolare e utilizzare fili di minor diametro

ELSEVIER

INJURY

www.elsevier.com/locate/injury

Rimodellamento

Principles of fracture remodeling in children

Kaye E. Wilkins

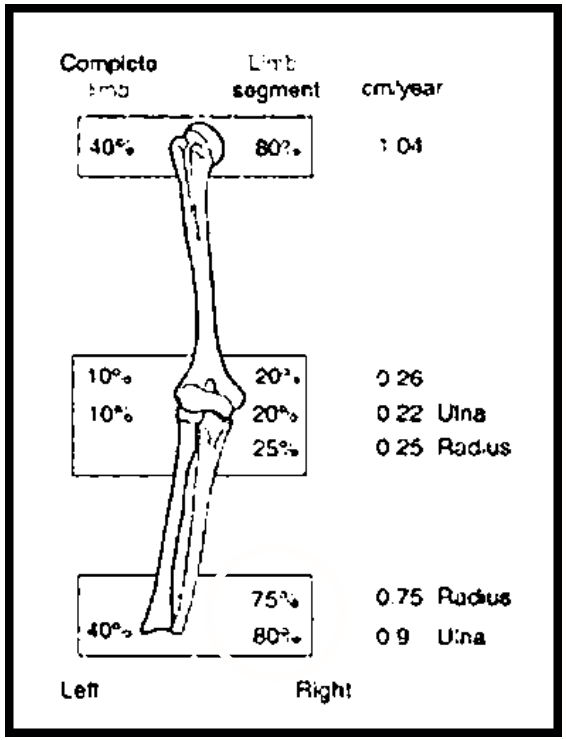

"…distal radial fractures have **tremendous** inherent remodeling potential…"

metafisi > diafisi

RIMODELLAMENTO

Limiti di tollerabilità SSE <10-12 anni

- 20°-30° di angolazione sul piano sagittale
- 50-70% di traslazione del frammento distale del radio
- Accorciamento fino ad 1 cm
- 10° angolazione radio-ulna nel piano coronale (AP)

TRASLAZIONE in AP
ANGOLAZIONE in LL
ANGOLAZIONE in AP

Friberg KS: Remodelling after distal forearm fractures in children. III. Correction of residual angulation in fractures of the radius, *Acta OrthopScand* 50:741-749, 1979.

. Do TT, Strub WM, Foad SL, et al: Reduction versus remodeling in ediatric distal forearm fractures: a preliminary cost analysis, *J Pediatr Orthop* 12:109-115, 2003.

7 anni
Rimodellamento
a 1 mese

WWW.PIETROPERSIANI

WWW.PIETROPERSIANI.IT

28 GG www



3MESI

ACCETTARE
SOPRA I 10AA 15° DI ANGOLAZIONE
SOTTO I 10AA 30° DI ANGOLAZIONE



"For Salter-Harris type I and II injuries in children younger than 10 years of age, angulation of up to 30° can be accepted. In children older than 10 years, up to 15° of angulation is generally acceptable."

Armstrong et al, *Skeletal Trauma*, 1998.

PERDITA DI RIDUZIONE

Circa 1/3 delle fratture di radio distale presentano perdita di riduzione

QUANDO PUO' SUCCEDERE??

- Scomposizione iniziale (baionetta, traslazione >50%, angolazione >30)
- Frattura isolata del radio distale
- Frattura biossea radio-ulna con rima allo stesso livello
- Riduzione inadeguata
- Inadeguato apparecchio gessato …

CONTROLLO RDX DOPO 4-5GG

Mani GV, Hui PW, Cheng JC: Translation of the radius as a predictor of outcome in distal radial fractures of children, *J Bone Joint Surg Br* 75:808-811, 1993.
Gibbons CL, Woods DA, Pailthorpe C, et al: The management of isolated distal radius fractures in children, *J Pediatr Orthop* 14:207- 210, 1994.
Proctor MT, Moore DJ, Paterson JM: Redisplacement after manipulation of distal radial fractures in children, *J Bone Joint Surg Br* 75:453- 454, 1993.

10 anni
Riduzione soddisfacente

Perdita della riduzione
Dopo 5 giorni

Osteosintesi con fili di K

Controllo a 17 gg

3 mesi dopo

Complicanze

- Lesione nervo mediano

- Avulsione stiloide ulnare (lesione Galeazzi simile)

  - Malunion
  - Nonunion

    Vere rarità…

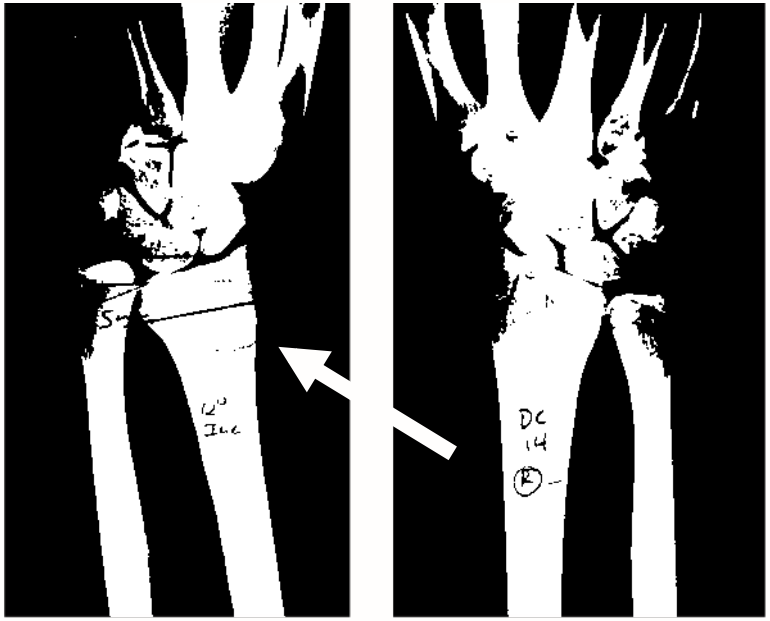

Niki



WWW.PIETROPERSONI.IT

M.T. 14 anni

Controllo a 15gg

Controllo a 40 gg

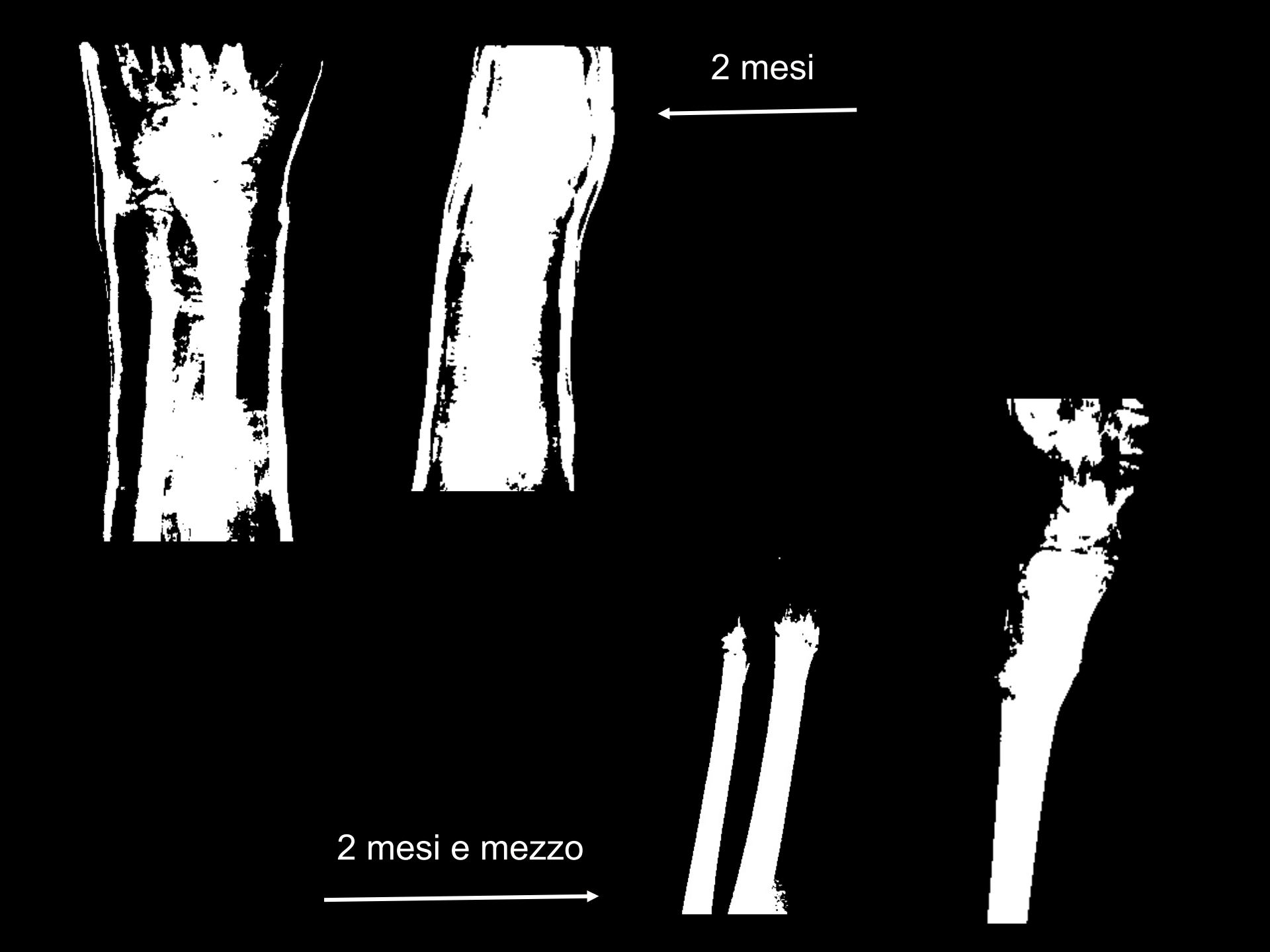
2 mesi
2 mesi e mezzo

mesi

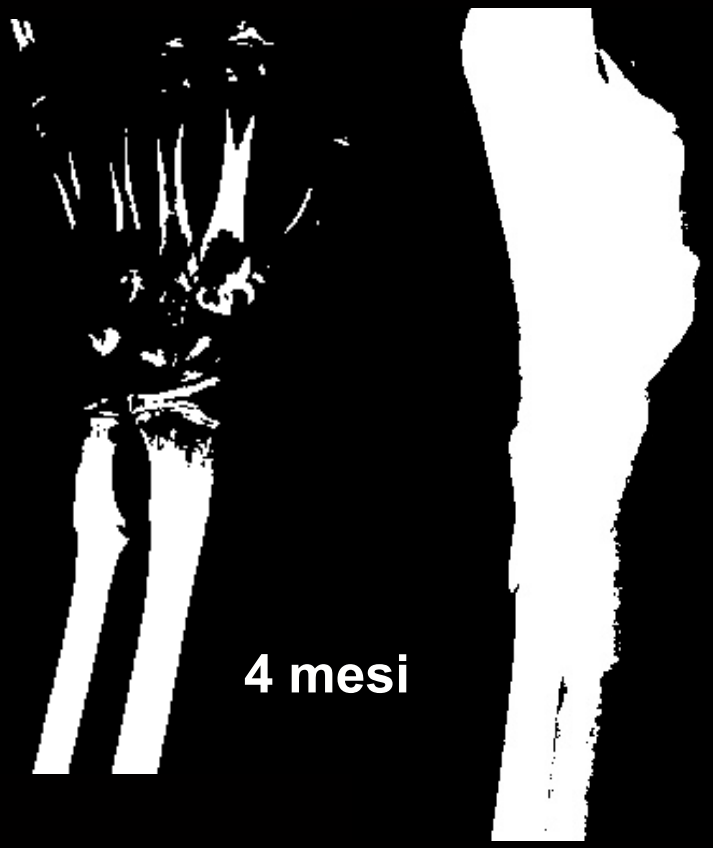
4 mesi

6 mesi aspetto ipertrofico



8 mesi



9 mesi

1 anno

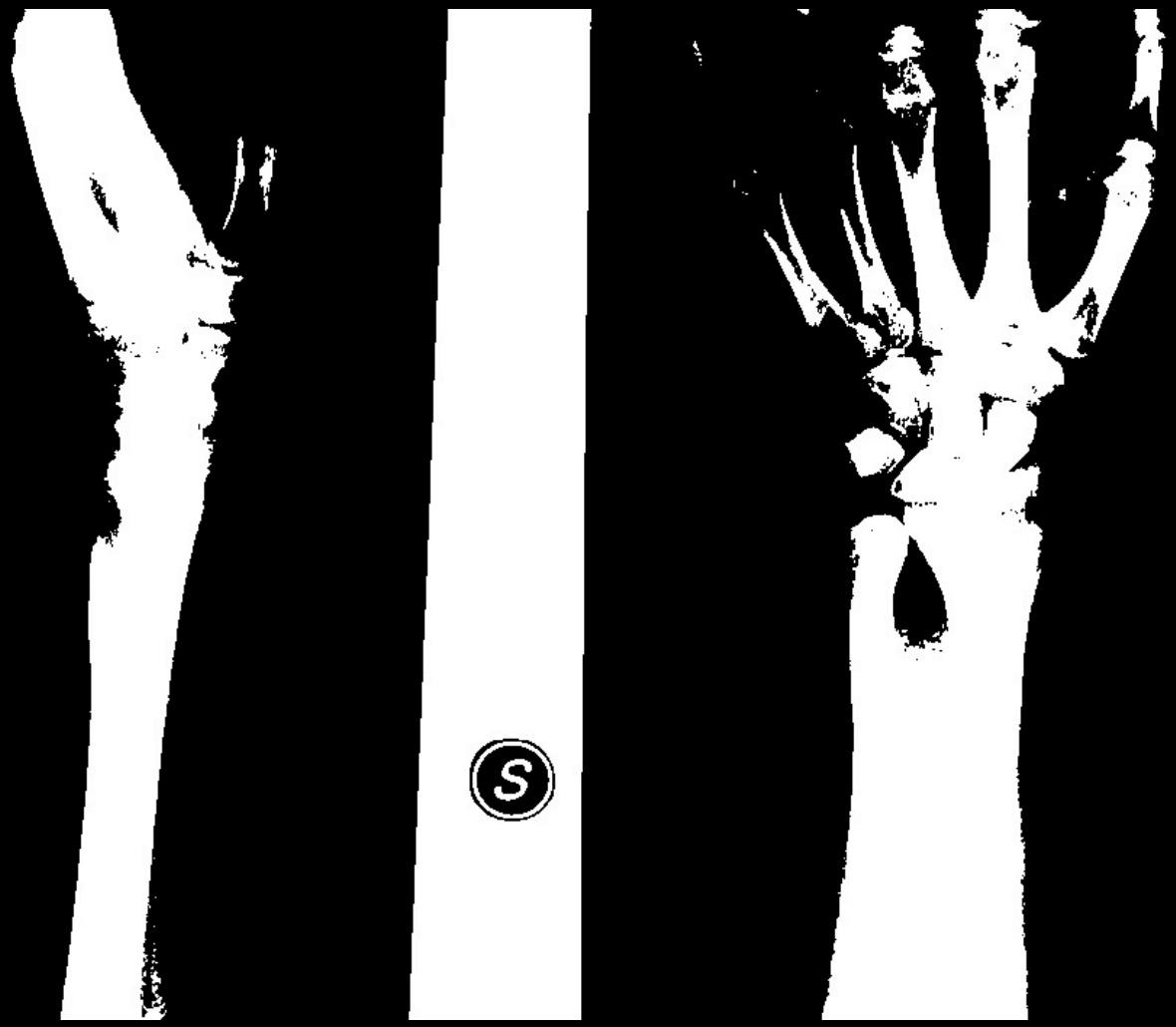

ARRESTO DELLA CRESCITA

- Severità del trauma
- Entità della scomposizione
- Ripetuti tentativi di riduzione
- Rimanipolazione o tardiva riduzione

Lesione fisi distale ulna
(50% rischio alterazione della crescita ossea)
Lesione fisi distale radio
(4-5% rischio alterazione della crescita ossea)

Conclusioni

- LA PIU **FREQUENTE** CAUSA DI ACCESSO AL PS IN ETA PEDIATRICA
- LA MAGGIOR PARTE TRATTATI CON **TRATTAMENTO INCRUENTO**
- ALTO POTENZIALE DI **RIMODELLAMENTO**
- **LIMITI DI TOLLERABILITÀ** (NEL BENE E NEL MALE)

Conclusioni

- SCOMPOSIZIONE SECONDARIA NEL **30%**
- **MEGLIO LASCIARE UNA FRATTURA PARZIALMENTE COMPOSTA** CHE ESEGUIRE MANOVRE DI RIDUZIONE CRUENTE CHE POSSONO DANNEGGIARE LA FISI
- LESIONI DELLA **FISI ULNARE** SONO ASSOCIATE A UN **RISCHIO MAGGIORE** DI ALTERAZIONE DELLA CRESCITA OSSEA (50%) RISPETTO A QUELLE DELLA FISI RADIALE (4-5%)

GRAZIE