SAPIENZA
UNIVERSITÀ DI ROMA

Pietro Persiani
Clinica Ortopedica
"Sapienza"
Università di Roma"

La Traumatologia Pediatrica

IV ORTHOS PAIDOS 2017

CASI DIFFICILI E CASI RARI

CASI “DIFFICILI”

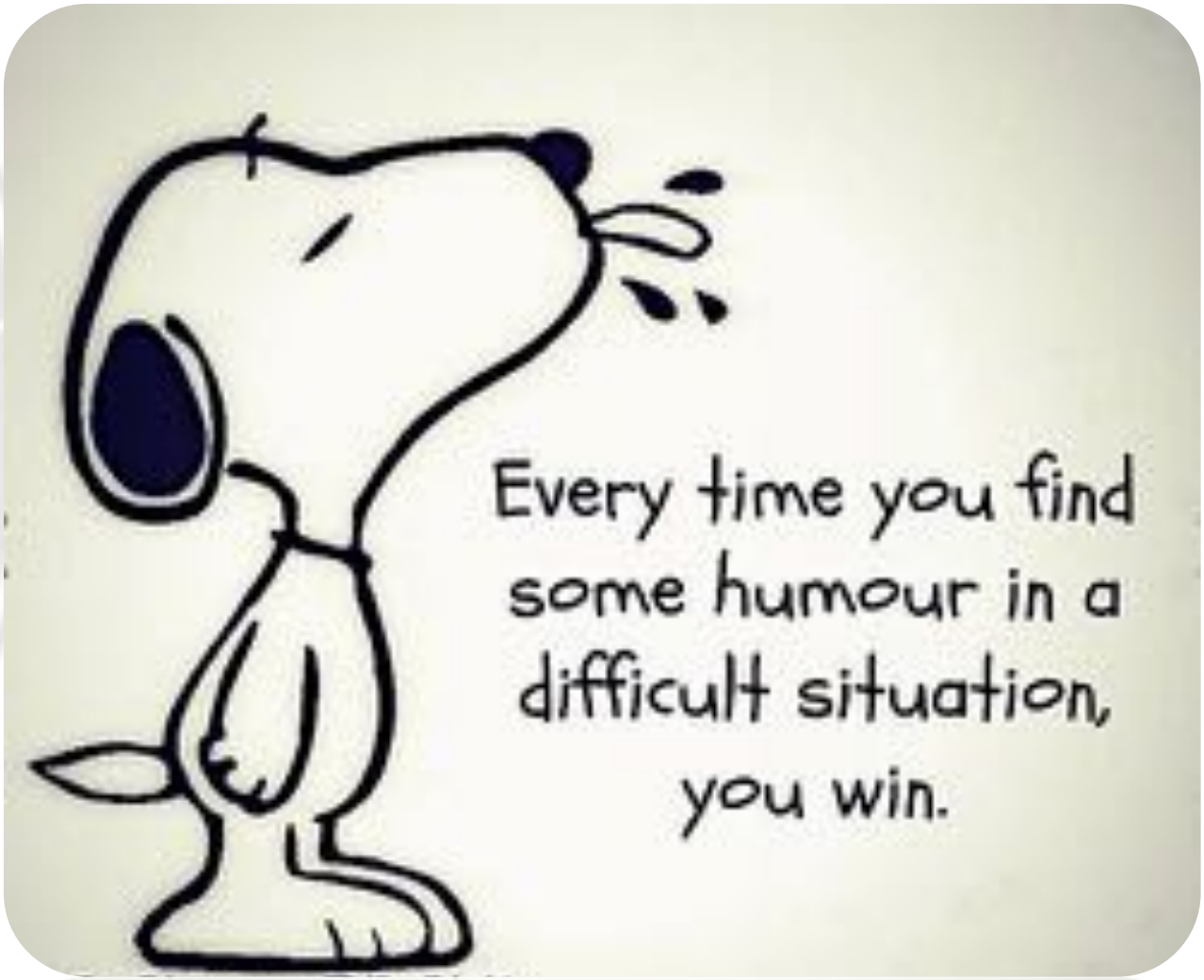

MI RACCOMANDO: NON DEVE CARICARE….

MI RACCOMANDO: NON DEVE CARICARE….

PRIMA DI GRATTARSI CON LA PENNA… TOGLIERE IL TAPPO

MISTERO SVELATO:
"…ECCO DOV'ERA IL MAGNETE DEL FRIGO…"

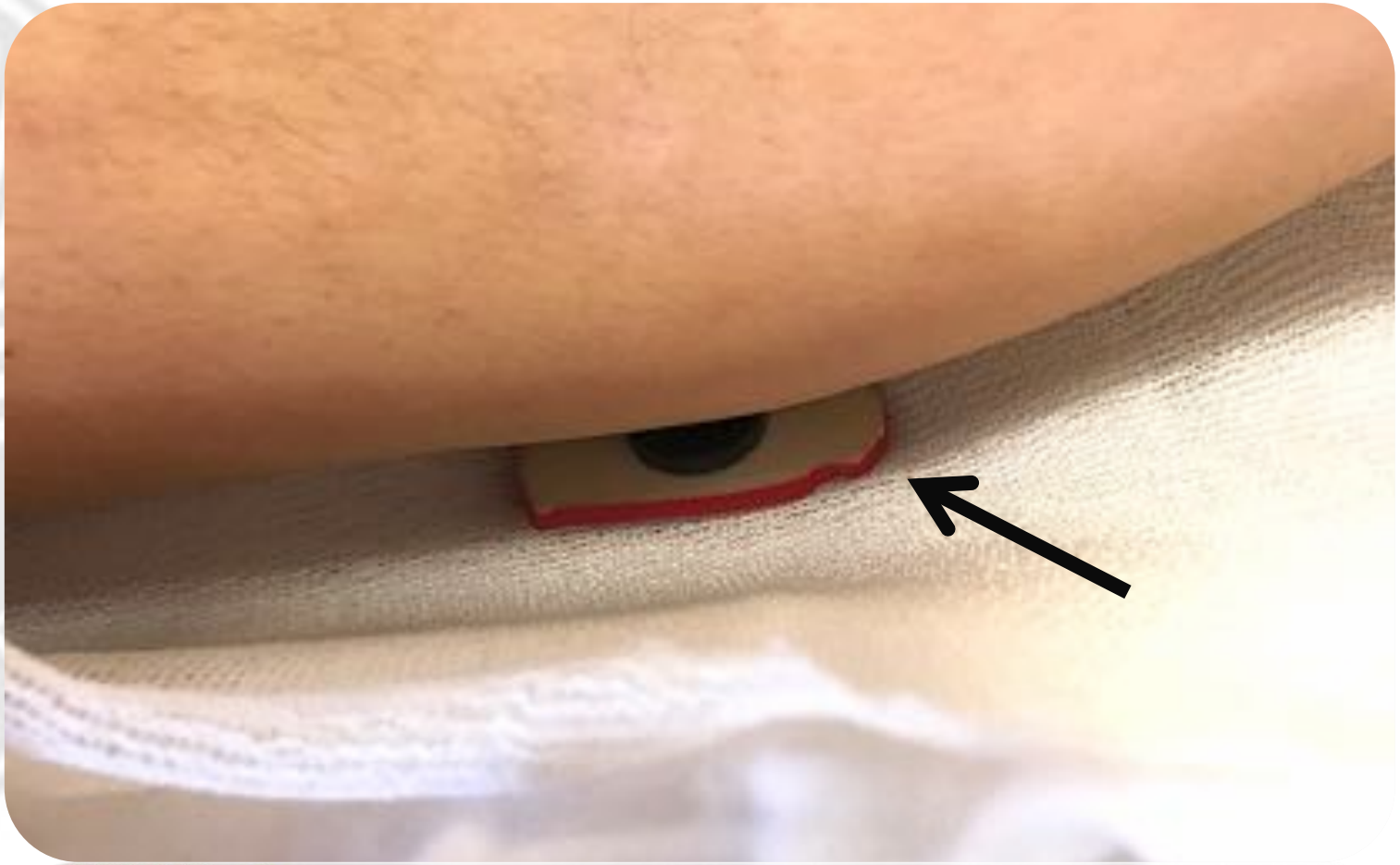

ALTRO MISTERO SVELATO:
IL LANCIATORE DI BAYBLADE

HO UN SASSOLINO…

SOMETIMES
YOU WIN
SOMETIMES
- YOU -
LEARN

CASI RARI E DIFFICILI

LE OSTEODISTROFIE CONGENITE

LE CEREBROPATIE INFANTILI

IL BAMBINO MALTRATTATO

OSTEODISTROFIE CONGENITE

OSTEOGENESI IMPERFETTA

MALATTIA RARA
1:20.000 NATI VIVI

EREDITARIA
COL1A1 E COL1A2

MALATTIA DELL'OSTEOBLASTA
MATRICE ANOMALA
IN QUANTITÀ E/O QUALITÀ

↑ ATTIVITÀ OSTEOCLASTI
TURNOVER OSSEO

Classificazione Sillence-Glorieux

- ETEROGENEITÀ CLINICA

FRATTURE SU DEFORMITA' E VICEVERSA

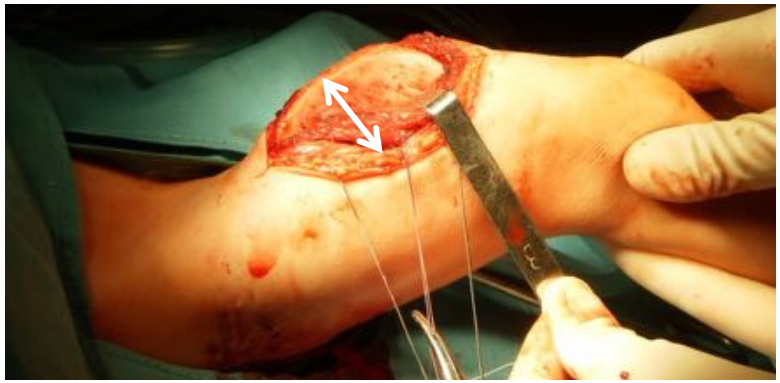

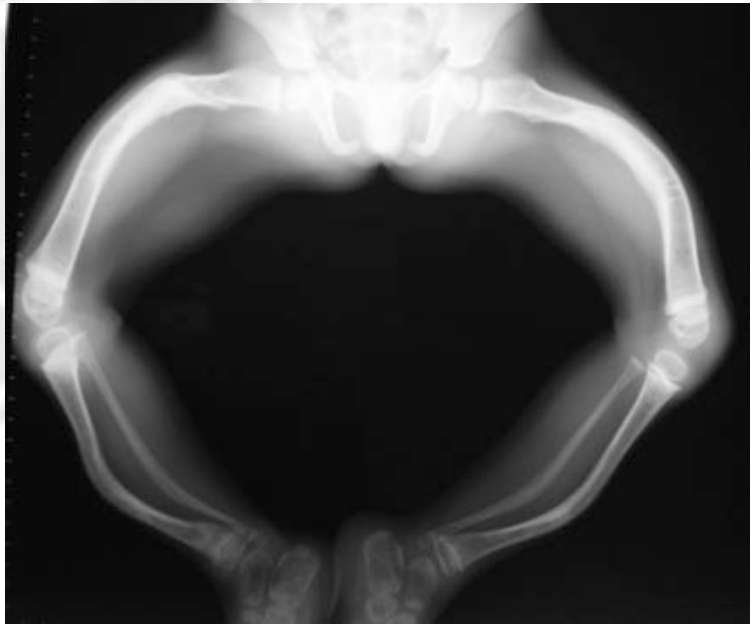

CURA e PREVENZIONE

OSTEOPETROSI

DISPLASIA OSSEA
MALATTIA DELL'OSTEOCLASTA: AUMENTO DENSITA' OSSEA

FORMA MALIGNA AUTOSOMICA RECESSIVA 1/250.000 NEONATI
FORMA AUTOSOMICA DOMINANTE 1/20.000 NEONATI

OSTEODISTROFIE CONGENITE

PARALISI CEREBRALI INFANTILI

OSTEOPOROSI
GMFS
COMUNICAZIONE

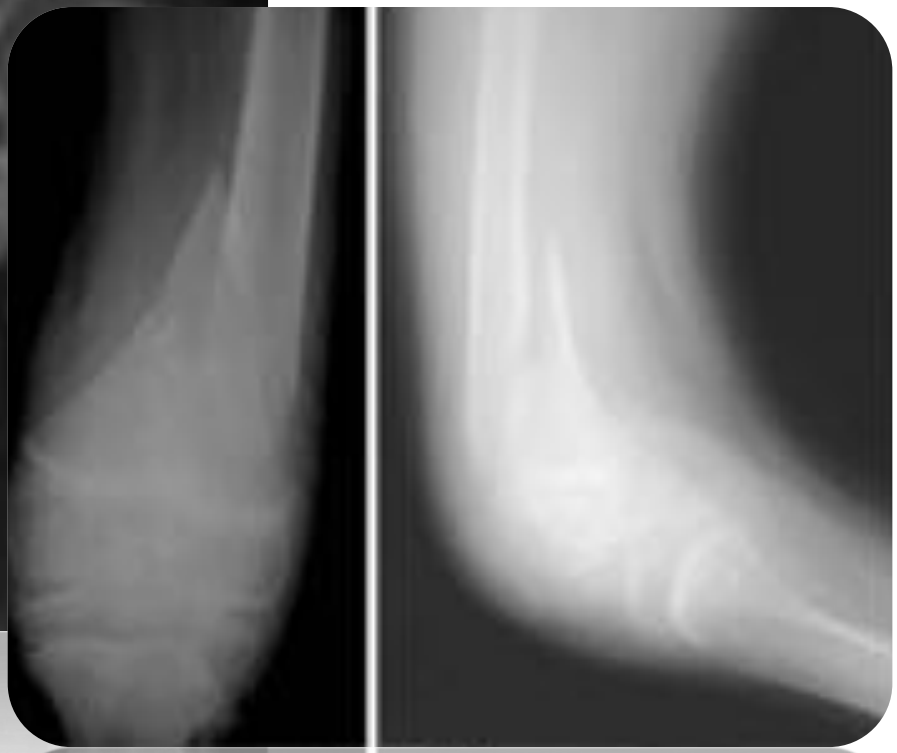

PARALISI CEREBRALI INFANTILI

9 ANNI DOPPIA EMIPARESI

SINTESI
PLACCA E VITI

FRATTURA SU PLACCA
DOPO 8 MESI

SINTESI
ENDOMIDOLLARE

CONTROLLO
A 4 MESI

IL BAMBINO MALTRATTATO (NON ACCIDENTAL INJURY)

THE INCIDENCE OF CHILD ABUSE IS DIFFICULT TO DETERMINE

The Journal of TRAUMA® *Injury, Infection, and Critical Care*

The Tip of the Iceberg for Child Abuse: The Critical Roles of the Pediatric Trauma Service and its Registry

David C. Chang, PhD, MPH, MBA, Vinita Knight, MPH, Susan Ziegfeld, MSN, CPNP, CCRN, Adil Haider, MD, MPH, Dawn Warfield, MSW, MPH, and Charles Paidas, MD

IL BAMBINO MALTRATTATO

Clin Orthop Relat Res (2011) 469:755–758
DOI 10.1007/s11999-010-1666-0

SYMPOSIUM: NONACCIDENTAL TRAUMA IN CHILDREN

The Classic

Multiple Fractures in the Long Bones of Infants Suffering From Chronic Subdural Hematoma

John Caffey MD

On the Theory and Practice of Shaking Infants

Its Potential Residual Effects of Permanent Brain Damage and Mental Retardation

John Caffey, MD, Pittsburgh

In the first modern discussion in 1946 of the parent-infant stress syndrome (PITS), or battered baby syndrome, I described six infants, 13 months or younger, who suffered from the combination of subdural hematomas and characteristic bone lesions.[4] During the last 25 years[5-9] substantial evidence, both manifest and circumstantial, has gradually accumulated which suggests that the whiplash-shaking and jerking of abused infants are common causes of the skeletal as well as the cerebrovascular lesions; the latter is the most serious acute complication and by far the most common cause of early death.[8]

Today we invite your attention to

line of demarcation between pathogenic and nonpathogenic shaking is often vague.

The nature and distribution of the bone lesions in the PITS must be interpreted from the radiographic changes exclusively because they have not been studied systematically at either surgical exploration or necropsy. The metaphyseal avulsions are the most common of these lesions. Some are small fragments of cortical bone torn off the external edge of the cortical wall at the metaphyseal levels where the periosteum is most tightly bound down to the cortex. In most cases, however, they appear to be small chunks of calcified cartilage which have been broken off the edges

CRITERI

KLEINMAN PK
DIAGNOSTIC IMAGING OF CHILD ABUSE. Editor MOSBY 1998

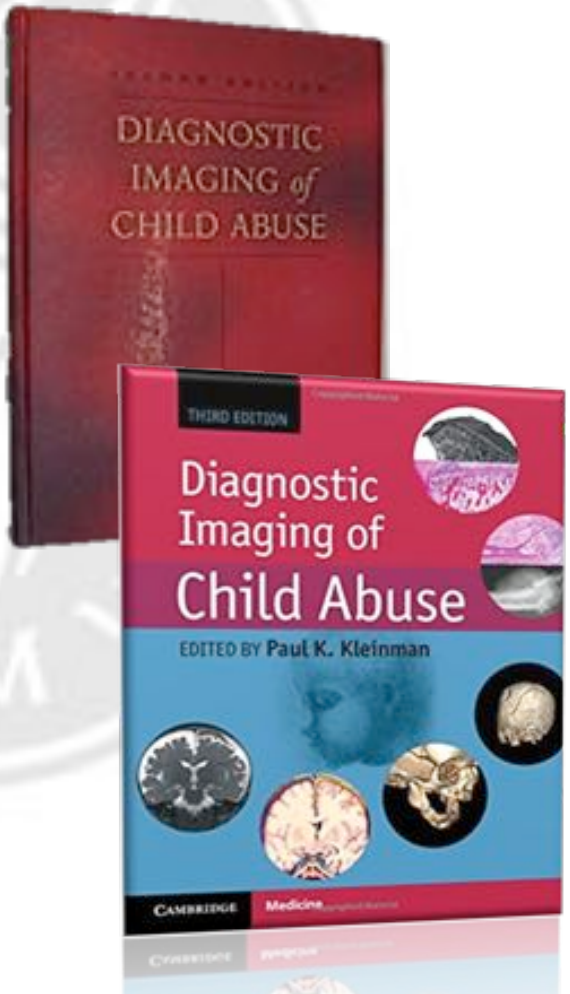

ETÀ ☑

MECCANISMO ☑

TIMING ☑

CRITERI

FRATTURE AD ALTA SPECIFICTA'

FRATTURE METADIAFISARIE CML
FRATTURE DI SCAPOLA, .VERTEBRALI, DEL CRANIO
FRATTURE DELLE DITA IN BAMBINI NON DEAMBULANTI
FRATTURE IN DIVERSO STATO DI GUARIGIONE

FATTORI CHE CHE AUMENTANO LA SPECIFICTA'

PICCOLA ETA'
ASSOCIAZIONE CON ALTRE LESIONI
STORIA INCONGRUENTE E RIFIUTO DEL RICOVERO
PREGRESSE FRATTURE NON RIFERITE

Child Abuse and Orthopaedic Injury Patterns: Analysis at a Level I Pediatric Trauma Center

Nirav K. Pandya, MD, Keith Baldwin, MD, MPH, MSPT,**

CML
CLASSIC METAPHYSEAL LESION

BUCKET HANDLE

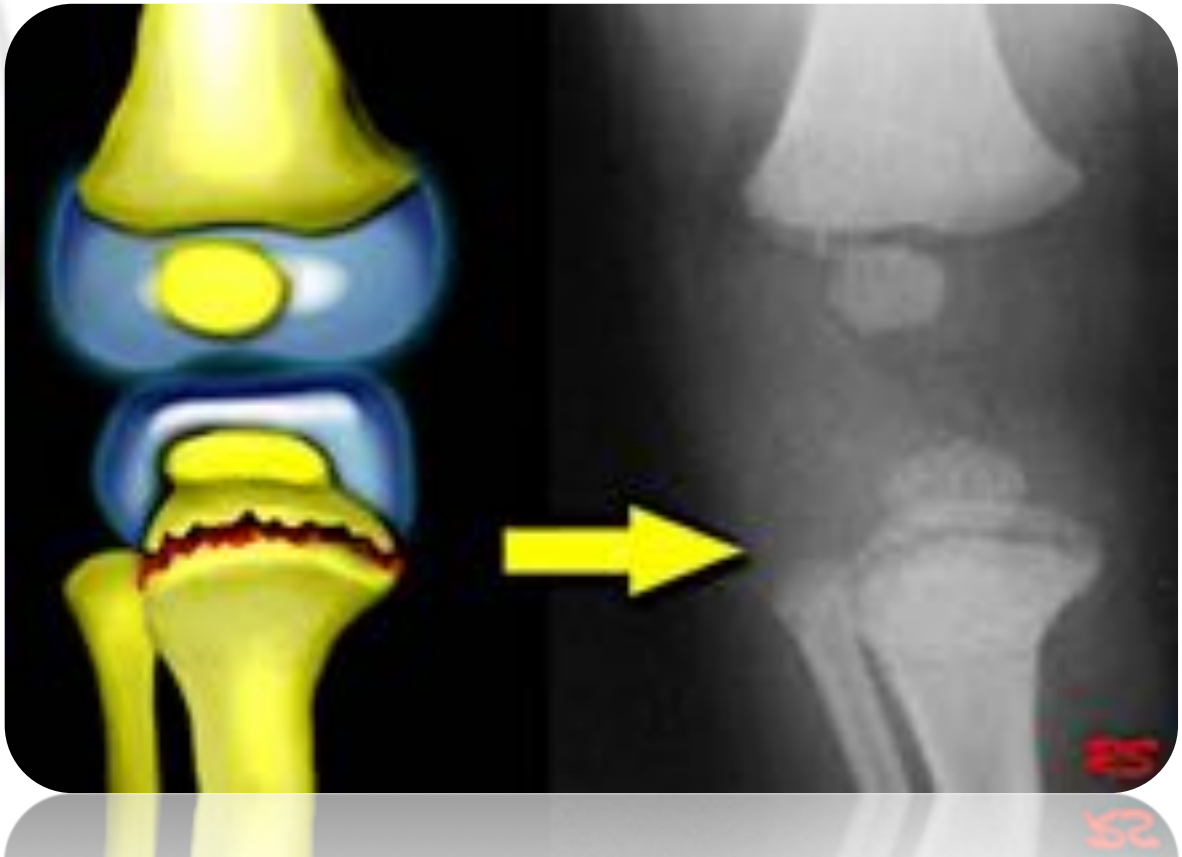

CML
CLASSIC METAPHYSEAL LESION

CORNER FRACTURE

FRATTURE DIAFISARIE

< 18 MESI

BILATERALI

NON GIUSTIFICABILI

FRATTURE COSTALI

CALLO OSSEO
DATING

DATING

	Time	Peak
Soft-tissue resolution	2 to 10 days	4 to 10 days
Early periosteal new bone	4 to 21 days	10 to 14 days
Loss of fracture line definition	10 to 21 days	14 to 21 days
Soft callus	10 to 21 days	14 to 21 days
Hard callus	14 to 90 days	21 to 42 days
Remodelling	3 mths to 2 yrs	



22

Child Abuse: Imaging and Legal Aspects

Claudio Defilippi and Roberta Cotti

CHAPTER 19

Radiological aspects of child abuse

K.T. Evans and G.M. Roberts

DATING

DATING

BUCKET HANDLE

REAZIONE PERIOSTALE

CORNER

DATING

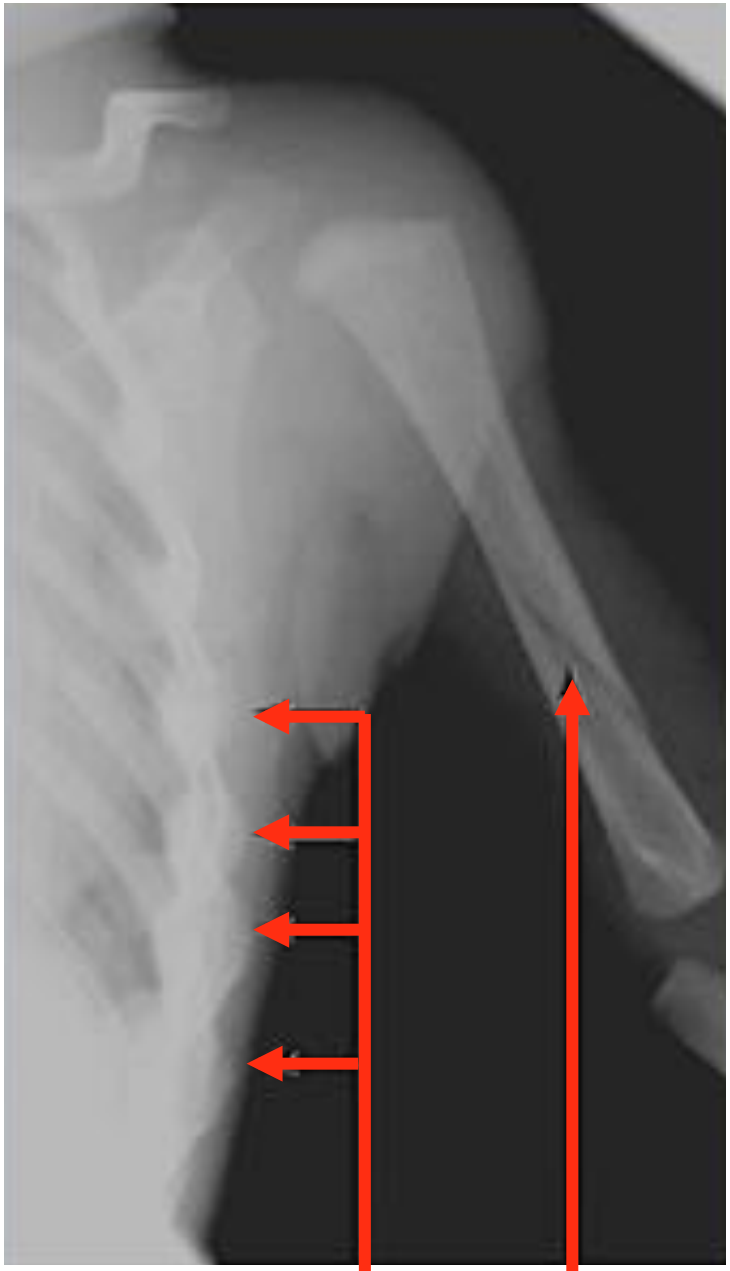

FR COSTALI IN GUARIGIONE

FR OMERALE RECENTE

FRATTURE DEL CRANIO E SINDROME SHAKEN BABY

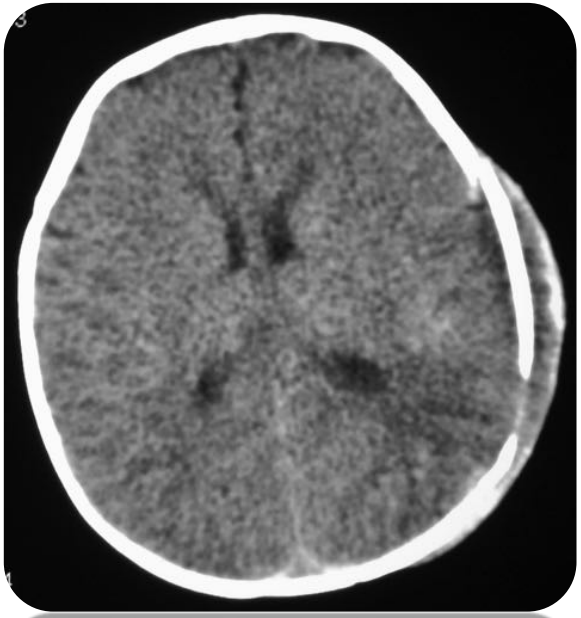

LEFT OCCIPITAL CONTUSION
SUBDURAL HYGROMA
SKULL FRACTURE

TESSUTI MOLLI

ESAMI

BABYGRAMMA

Skeletal Survey:

Obtain for all children ≤ 3 years old with possible child abuse.

- Appendicular skeleton:
  - Humeri (AP)
  - Forearms (AP)
  - Hands (oblique PA)
  - Femurs (AP)
  - Lower legs (AP)
  - Feet (PA or AP)

British Society of Paediatric Radiology

- Axial skeleton:
  - Thorax (AP, lateral, and obliques) to include thoracic spine and ribs
  - AP abdomen, lumbosacral spine, and bony pelvis
  - Lumbar spine (lateral)
  - Cervical spine (AP and lateral)
  - Skull (frontal and lateral)

SE SOSPETTO

RIPETERE DOPO 10gg

Follow-Up Skeletal Surveys in Suspected Child Abuse

Paul K. Kleinman[1]
Katherine Nimkin[1]
Melissa R. Spevak[1]
Shawn M. Rayder[1]
Deborah L. Madansky[2]
Yvonne A. Shelton[3]
Miki M. Patterson[3]

OBJECTIVE. The purpose of this study was to assess
etal survey in identifying and dating skeletal injury
strongly suspected.
MATERIALS AND METHODS. Twenty-three
of being physically abused on the basis of findings on
ing studies, history, or physical examination under
mately 2 weeks after the initial examination. The
single-emulsion, single-screen combination with a low-absorption
skeletal survey protocol entailed tightly collimated anteroposterior views of the a

AJR

DIAGNOSI DIFFERENZIALE

OSTEOGENESI IMPERFETTA

RACHITISMO, SCORBUTO

Patrizia D'Eufemia[1]
Marta Palombaro[1]
Valentina Lodato[1]
Anna Zambrano[1]
Mauro Celli[1]
Pietro Persiani[2]
Maria Pia De Bari[3]
Luca Sangiorgi[4]

Child abuse and osteogenesis imperfecta: how can they be still misdiagnosed? A case repo

Clinical Cases in Mineral and Bone Metabolism 2012; 9(3): 195-197



PERCORSI SPECIFICI AZIENDALI O REGIONALI

IL TEMPO.it

Chiuso il centro per i bambini abusati

Era l'unico a Roma e assisteva anche i giovani responsabili di reati sessuali Smantellato alla fine del 2015 per mancanza di fondi: servivano 100.000 euro

GARANTIRE PROTEZIONE IMMEDIATA

RICOVERO (PER DD)

CONSEGUENZE

GRAVI PER LA FAMIGLIA
SE DIAGNOSI NON CORRETTA

MA FATALI PER IL BAMBINO
SE DIAGNOSI MISCONOSCIUTA

THE REINJURY RATE 30% - 50%
THE RISK OF DEATH 5% - 10%

THM

PRESENTAZIONI DIVERSE

PAZ ALTO RISCHIO < 18 MESI

CML (corner o BUCKET HANDLE)

FR COSTALI E DIAFISARIE (ANAMNESI)

RICERCA RDX E FOLLOW UP (DATING)

PROTEZIONE IMMEDIATA

DIAGNOSI DIFFERENZIALE

GRAZIE

pietro.persiani@uniroma1.it